Overhead Squat Test

Dong Koog Noh P.T., Ph.D.


Overhead Squat Position
Anterior
Lateral
Posterior

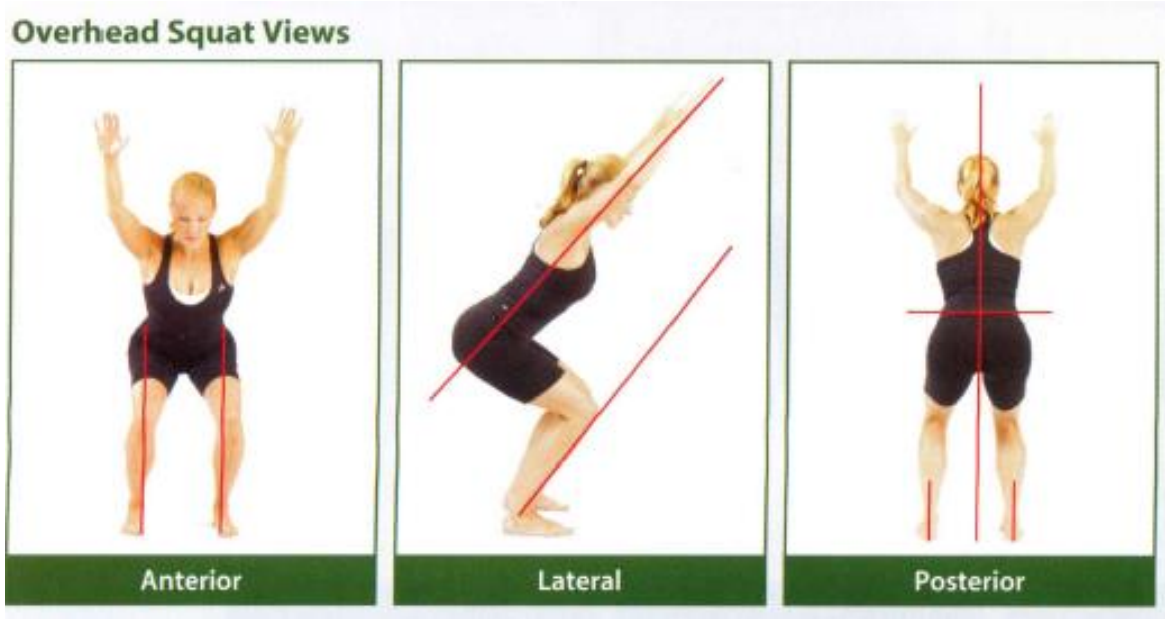
Overhead Squat Views
Anterior
Lateral
Posterior

Overhead Squat Compensations, Anterior View

Overhead Squat Compensations, Lateral View

Overhead Squat Compensations, Posterior View

MOVEMENT COMPENSATIONS FOR THE OVERHEAD SQUAT ASSESSMENT

View	Checkpoint	Compensation	Probable Overactive Muscles	Probable Underactive Muscles	Possible Injuries
Anterior	Feet	Turns Out	Soleus Lat. Gastrocnemius Biceps Femoris (short head) Tensor Fascia Latae (TFL)	Med. Gastrocnemius Med. Hamstring Gluteus Medius/Maximus Gracilis Popliteus Sartorius	Plantar fasciitis Achilles tendinopathy Medial tibial stress syndrome Ankle sprains Patellar Tedinopathy (jumper's knee)
		Flatten	Peroneal Complex Lat. Gastrocnemius Biceps Femoris TFL	Anterior Tibialis Posterior Tibialis Med. Gastrocnemius Gluteus Medius	
	Knees	Move Inward (Valgus)	Adductor Complex Biceps Femoris (short head) TFL Lat Gastrocnemius Vastus Lateralis	Med. Hamstring Med. Gastrocnemius Gluteus Medius/ Maximus Vastus Medialis Oblique (VMO) Anterior Tibialis Posterior Tibialis	Patellar tendinopathy (jumpers knee) Patellofemoral Syndrome ACL Injury IT band tendonitis
		Move Outward	Piriformis Biceps Femoris TFL/Gluteus Minimus	Adductors Complex Med. Hamstring Gluteus Maximus	

MOVEMENT COMPENSATIONS FOR THE OVERHEAD SQUAT ASSESSMENT (*CONTINUED*)

View	Checkpoint	Compensation	Probable Overactive Muscles	Probable Underactive Muscles	Possible Injuries
Lateral	LPHC	Excessive Forward Lean	Soleus Gastrocnemius Hip Flexor Complex Piriformis Abdominal Complex (rectus abdominus, external oblique)	Anterior Tibialis Gluteus Maximus Erector Spinae Intrinsic Core Stabilizers (transverse abdominis, multifidus, transversospinalis, internal oblique, pelvic floor muscles)	Hamstring, quad & groin strain Low back pain
		Low Back Arches	Hip Flexor Complex Erector Spinae Latissimus Dorsi	Gluteus Maximus Hamstrings Intrinsic Core Stabilizers	
		Low Back Rounds	Hamstrings Adductor Magnus Rectus Abdominis External Obliques	Gluteus Maximus Erector Spinae Intrinsic Core Stabilizers Hip Flexor Complex Latissimus Dorsi	
	Shoulders	Arms Fall Forward	Latissimus Dorsi Pectoralis Major/ Minor Coracobrachialis Teres Major	Mid/Lower Trapezius Rhomboids Posterior Deltoid Rotator Cuff	Headaches Biceps tendonitis Shoulder injuries
Posterior	Foot	Foot Flattens	Peroneal Complex Lat. Gastrocnemius Biceps Femoris (short head) TFL	Anterior Tibialis Posterior Tibialis Med. Gastrocnemius Gluteus Medius	Plantar fascitis Achilles tendinopathy Medial tibial stress syndrome Ankle sprains Patellar Tedinopathy (jumper's knee)
		Heel of Foot Rises	Soleus	Anterior Tibialis	
	LPHC	Asymmetrical Weight Shift	Adductor Complex TFL (same side of shift) Gastrocnemius/ soleus Piriformis Bicep Femoris Gluteus Medius (opposite side of shift)	Gluteus Medius, (same side of shift) Anterior Tibialis Adductor Complex (opposite side of shift)	Hamstring, Quad & Groin strain Low back pain SI joint pain

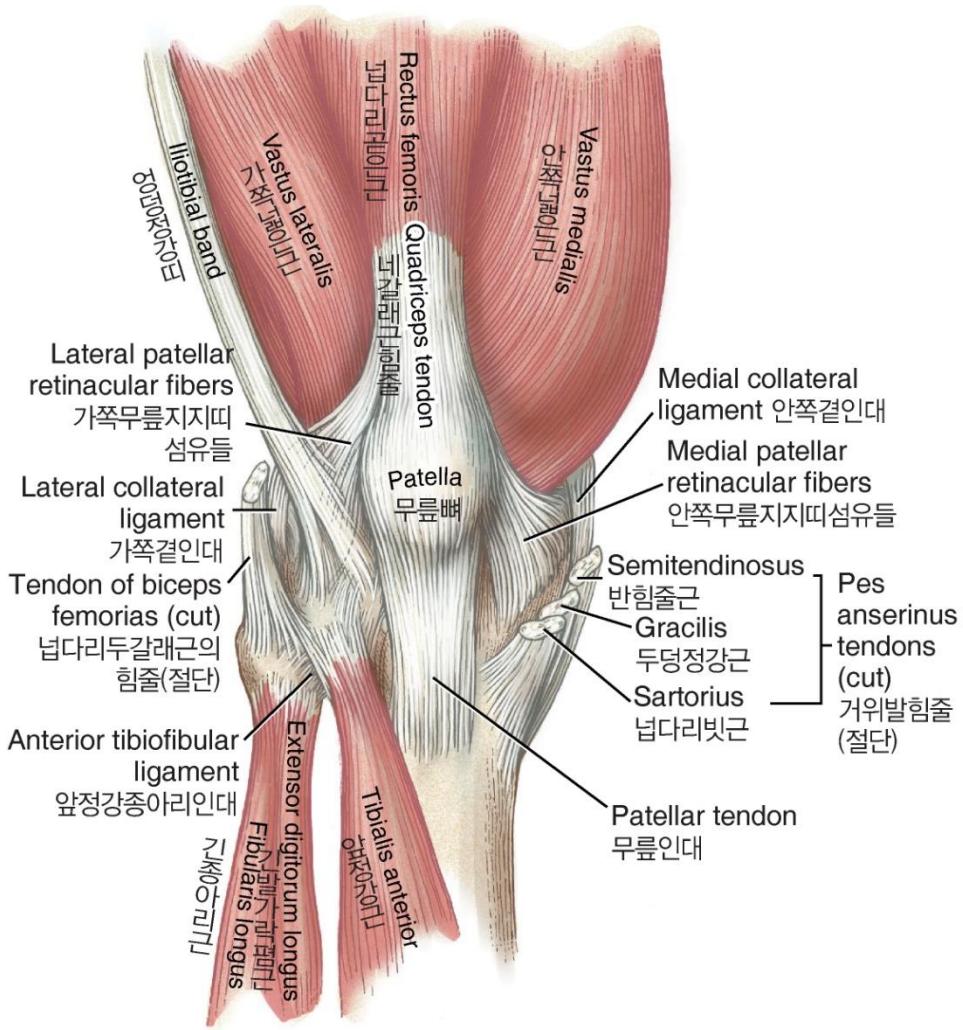

그림 13-7. 많은 근육과 결합조직에 초점을 둔 오른쪽 무릎의 앞면. 거위발 힘줄들은 안쪽곁인대와 안쪽무릎지지띠를 노출시키기 위해 제거되었다.

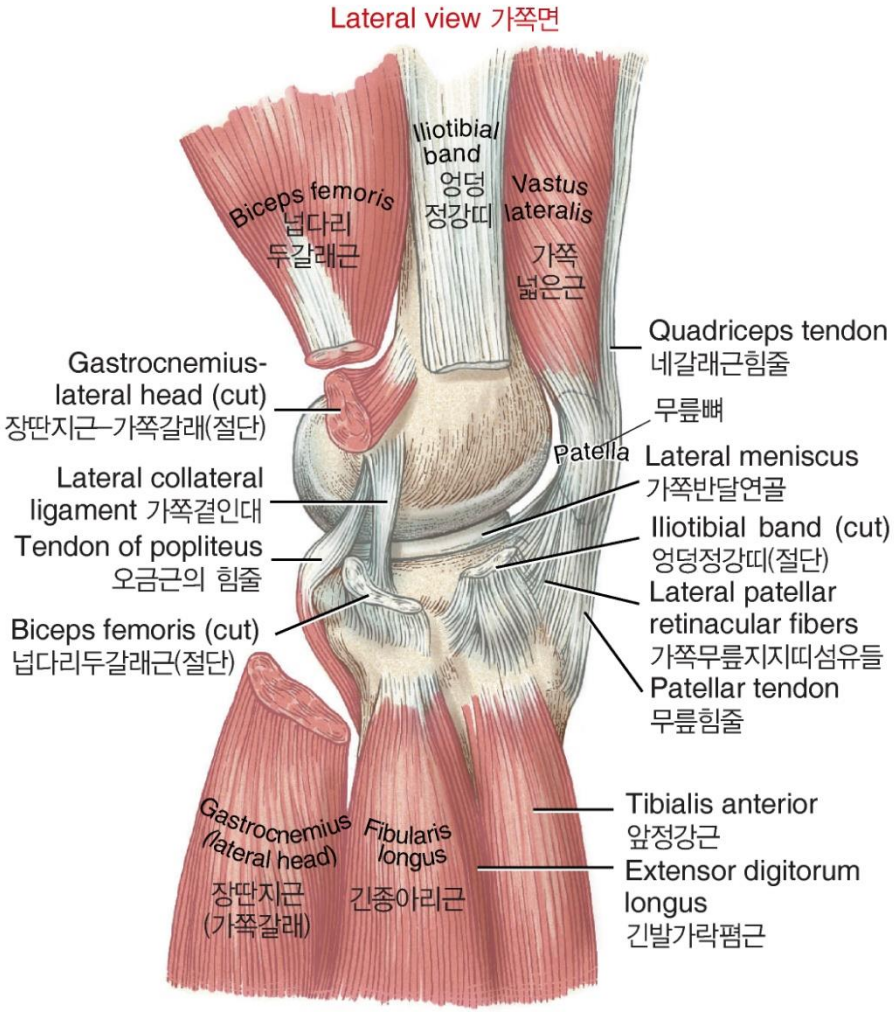

그림 13-8. 많은 근육과 결합조직을 보여주고 있는 오른쪽 무릎관절의 가쪽면. 엉덩정강띠, 장딴지근의 가쪽갈래, 그리고 넙다리두갈래근은 가쪽곁인대, 오금근힘줄, 그리고 가쪽반달연골을 좀 더 보여주기 위해 제거되었다.

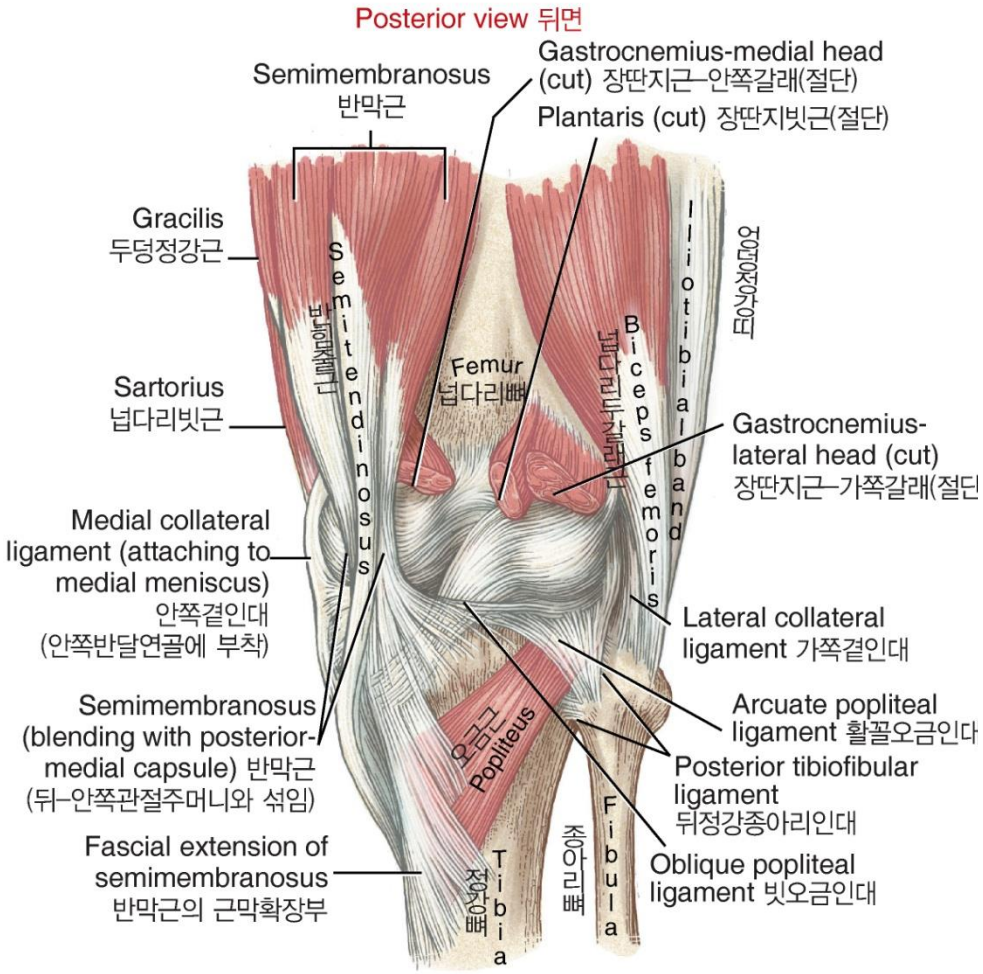

그림 13-9. 뒤관절주머니의 주요 부분인 빗오금인대와 활꼴오금인대를 강조한 오른쪽 무릎의 뒤면. 장딴지근의 가쪽갈래와 안쪽갈래 그리고 장딴지빗근은 뒤관절주머니를 노출시키기 위해 제거되었다. 다리오금의 깊은 쪽에 있는 오금근은 반막근의 근막 확장부에 의해 부분적으로 덮여 있다.

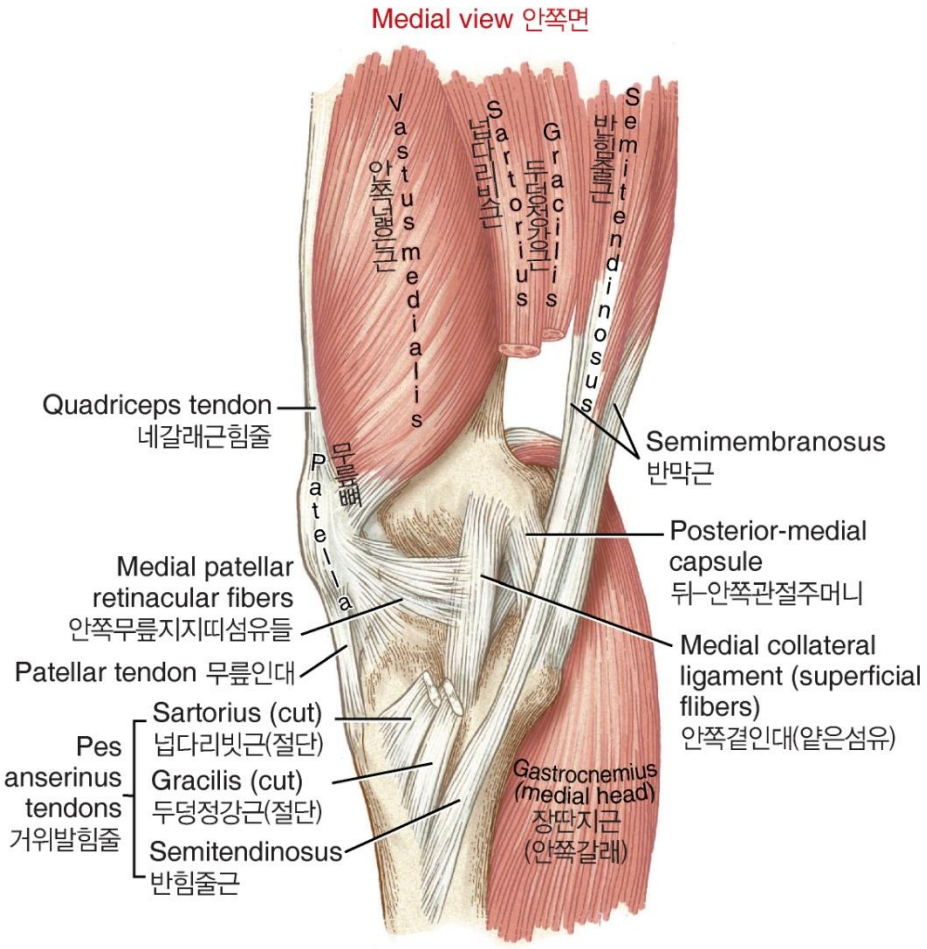

그림 13-10. 많은 근육과 결합조직을 보여주고 있는 오른쪽 무릎의 안쪽면. 넙다리빗근과 두덩정강근의 힘줄들은 안쪽곁인대의 얕은부위와 뒤–안쪽관절주머니를 좀 더 노출시키기 위해 제거되었다.